



**PATIENT**

Daisy Garnage

**SPECIES**

Canine

**BREED**

Jack Russell Terrier

**SEX**

Female Spayed

**AGE**

7 years

**WEIGHT**

13.2lbs

**INTERPRETED BY**

Maggie Machen  
Lamy, DVM  
DACVIM (Cardiology)

**IMAGING PERFORMED BY**

Pamela Harrigan,  
RDCS

**HOSPITAL NAME**

Rhode Island Animal  
Medical Center

**REFERRING VET**

Dr. Hart

**INVOICE**

20674

**DATE**

8/20/21

**PRESENTING CLINICAL SIGNS**

History: Asymptomatic grade III/VI systolic murmur. BP: 150mmHg. \*Sedated with torb/midazolam.

**ECHOCARDIOGRAM FINDINGS**

2D, m-mode, color flow and Doppler imaging is available.

**Left ventricle:** The LV diameter is normal with adequate myocardial function. LV wall thicknesses are normal.

**Left atrium:** The left atrium is normal.

**Mitral valve:** The mitral valve is mildly thickened with no prolapse into the left atrial lumen. Mild eccentric mitral regurgitation.

**Aortic valve/aorta:** The aortic valve is normal in morphology and mobility. Normal aortic outflow velocity; laminar flow. No aortic insufficiency.

**Right ventricle:** Normal right ventricular diameter and morphology indicating no overt evidence of pulmonary arterial hypertension.

**Right atrium:** Normal RA dimension.

**Tricuspid valve:** The tricuspid valve appears thickened with mild septal prolapse and mild tricuspid regurgitation; borderline normal velocity.

**Pulmonic valve/pulmonary artery:** The pulmonic valve is normal in morphology and mobility. No pulmonic insufficiency. Normal RVOT velocity; laminar flow.

**Pericardium/other:** No pericardial or pleural effusion noted. No obvious cardiac masses.

**Heart rhythm:** ECG reveals a sinus rhythm with an average HR of 110bpm.

**2-Dimensional Measurements**

Ao diam (cm)	1.5
LA diam (cm)	1.68
LA:Ao (Swe)	1.1
IVS thickness (cm)	0.67
LVID diastole (cm)	2.6
PW thickness (cm)	0.66
LVID systole (cm)	1.5
FS (%)	41

**Doppler Measurements**

PV Vmax (m/s)	0.6
AoV Vmax (m/s)	1.0
MR Vmax (m/s)	NM
TR Vmax (m/s)	2.6
TR PG (mmHg)	27

**INTERPRETATION OF THE FINDINGS**

The cause of the murmur is chronic degenerative valve disease causing mild mitral and tricuspid regurgitation. Lack of significant left atrial enlargement indicates the current risk for complication is low. No concurrent issues such as systolic dysfunction or pulmonary hypertension are noted in this study. Assessment of progression in the future will help predict long term prognosis, which is highly variable at this stage (B1).

**RECOMMENDATIONS**

- In an asymptomatic dog without significant left atrial enlargement, no cardiac medications are clearly indicated.



**PATIENT**

Daisy Garnage

**SPECIES**

Canine

**BREED**

Jack Russell Terrier

**SEX**

Female Spayed

**AGE**

7 years

**WEIGHT**

13.2lbs

**INTERPRETED BY**

Maggie Machen  
 Lamy, DVM  
 DACVIM (Cardiology)

**IMAGING PERFORMED BY**

Pamela Harrigan,  
 RDCS

**HOSPITAL NAME**

Rhode Island Animal  
 Medical Center

**REFERRING VET**

Dr. Hart

**INVOICE**

20674

**DATE**

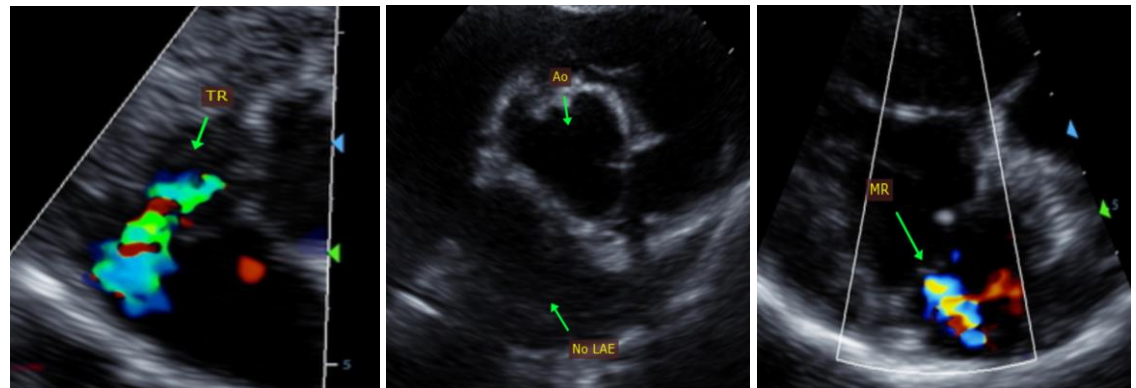
8/20/21

- Omega fatty acid supplementation and mild salt restriction may be of some long-term benefit.
- No cardiac contraindication for general anesthesia prior to chamber enlargement.
- Monitor for development of a cough, labored breathing, exercise intolerance or collapse episodes.

**PLAN**

- Recommend conservative monitoring with a recheck echocardiogram in 6 months, sooner if any development of clinical signs.

**IMAGES**



**The information and recommendations provided are based on the images presented by the referring veterinarian. No evaluation can be communicated regarding pathology that was not visible in the image/video clips provided.**

Thank you for this referral. This report was generated using transcription software, and minor dictation errors may be present. If the clinical or image interpretation does not parallel your findings or if I can be of any further assistance, please contact me.

**Maggie Machen Lamy, DVM**  
**Diplomate of the American College of Veterinary Internal Medicine (Cardiology)**  
 info@sonopath.com